

# Esophageal Stricture Following Radiation, Concurrent Immunochemotherapy, Treated With Hyperbaric Oxygen and Dilation

Olayinka D. Ajayi, MD; Cadman L. Leggett, MD;  
Sarel J. Myburgh, APRN, CNP, MSN; Stephen M. Hendriksen, MD;  
Christopher J. Logue, MD; Joseph W. Walter, MD; Thomas C. Masters, MD;  
and Bjorn C. Westgard, MD

## Abstract

Low-dose palliative radiation may offer symptomatic relief in patients with spinal metastases from primary renal cell cancer and is unlikely to result in radiation injury. Patients with advanced malignancy requiring palliative radiation are often also receiving chemotherapy. Synergistic adverse effects resulting from combined palliative radiation and novel antiprogrammed cell death-1 (anti-PD 1) and/or multityrosine kinase inhibitors are rare.

We report about a 60-year-old woman with metastatic clear-cell renal cancer, status post-left nephrectomy, with debilitating mid-back pain from metastatic tumor burden and foraminal nerve compression. Her chemotherapeutic regimen was repeatedly altered because of progression of disease until she was maintained on the anti-PD 1 checkpoint inhibitor, nivolumab. She received palliative radiation to her thoracic spine over a 2-week period, and nivolumab was then switched to cabozantinib midway through a course of palliative radiation. The patient rapidly developed severe esophagitis, progressing to esophageal stricture, and required placement of a percutaneous endoscopic gastrostomy tube. She was successfully treated with serial esophageal dilation and hyperbaric oxygen treatments to diminish inflammation and improve tissue vascularity. Concurrent use of anti-PD 1 and/or multityrosine kinase drugs may accelerate development of radiation injury regardless of radiation dosage. Radiation-induced esophageal stricture was managed successfully in this patient with serial esophageal dilation and adjuvant hyperbaric oxygen.

© 2019 THE AUTHOR. Published by Elsevier Inc on behalf of Mayo Foundation for Medical Education and Research. This is an open access article under the CC BY-NC-ND license (<http://creativecommons.org/licenses/by-nc-nd/4.0/>) ■ Mayo Clin Proc Inn Qual Out 2019;3(2):241-245

We present the case of a patient with esophageal stricture caused by palliative radiation for metastatic renal cell cancer and worsened by concurrent antiprogrammed cell death (PD) receptor and tyrosine kinase inhibitor medications, that was successfully treated with serial dilation and adjuvant hyperbaric oxygen (HBO) therapy. Palliative radiation and concurrent immune checkpoint inhibitors with or without chemotherapy have led to improved survival rates among patients with metastatic renal cell cancer.<sup>1-3</sup> Clinical studies suggest concurrent radiation and chemotherapy regimens portends increased acute

and chronic adverse radiation events.<sup>4,5</sup> Esophageal stricture is a well-recognized late adverse event of head, neck, or thoracic radiation, but it is uncommon to have a stricture develop following palliation-level doses of radiation ( $\leq 30$  Gy).<sup>6,7</sup> Serial esophageal dilation has proved to be relatively successful in treating radiation-induced esophageal strictures, but recurrence remains problematic.<sup>8,9</sup> Gradually, over time, irradiated tissue becomes hypoxic, hypovascular, and hypocellular.<sup>10</sup> HBO improves tissue oxygenation, stimulates vasculogenesis, and angiogenesis, thereby creating a tissue bed ready for healing.<sup>11,12</sup> Hyperbaric oxygen has thus been shown to

From the Division of Hyperbaric Medicine, Department of Emergency Medicine, Hennepin Healthcare (O.D.A., S.M.H., C.J.L., J.W.W., T.C.M., B.C.W.), Division of Gastroenterology and Hepatology, Mayo Clinic (C.L.L., S.J.M.), and University of Minnesota Medical School, Minneapolis, MN (S.M.H., C.J.L., J.W.W., T.C.M., B.C.W.).

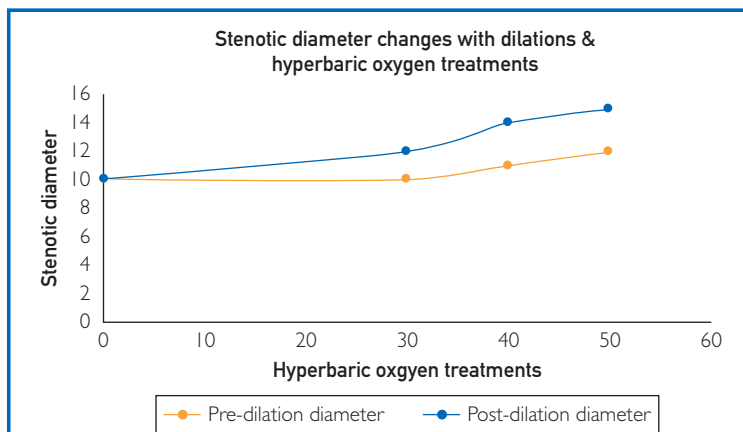
facilitate healing resulting from radiation-induced injury in non-neural tissue.<sup>13</sup>

## CASE

A 60-year-old woman with clear-cell renal cancer status post-left nephrectomy presented with metastatic disease to the thoracic spine and lungs 10 years following her initial diagnosis. She did not respond favorably to a chemotherapy regimen consisting of HD-interleukin-2, sorafenib, and pazopanib and had evidence of disease progression to the thoracic spine. The patient was subsequently treated with nivolumab as second-line therapy and underwent OsteoCool ablation (Medtronic, Minneapolis, MN) and kyphoplasty. The patient presented 6 months later with recurrent severe back pain. Restaging cross-sectional imaging studies showed metastatic tumor burden with nerve compression and invasion of spine, paraspinal metastasis with extension into the right neural foramina of the T10-T11 and T11-T12, causing significant stenosis. She was maintained on nivolumab and offered palliative thoracic radiation. The patient also received a total of 30 Gy to her thoracic spine via external-beam radiation over a 2-week period. On day 6 of radiation therapy, nivolumab was discontinued, and she was switched to cabozantinib.

During the second week of radiation therapy, she experienced severe dysphagia and odynophagia, requiring inpatient care for an inability to tolerate oral intake. An esophagogastroduodenoscopy (EGD) showed evidence of diffuse desquamation and ulceration of the mucosa in the mid- and distal esophagus consistent with severe radiation esophagitis. She was treated with high-dose acid-suppression therapy, with a combination of proton-pump inhibitors and histamine-2 receptor blockers. She required placement of a percutaneous endoscopic gastrostomy (PEG) tube for nutritional support. Repeat upper endoscopies performed at 3 and 5 months after receiving radiation therapy showed ongoing evidence of refractory radiation esophagitis with ulceration. Other etiologies for esophagitis, including viral and ischemic esophagitis, were ruled out.

The patient was enrolled in a serial esophageal dilation program and was referred for concomitant hyperbaric therapy. Her treatment plan involved an initial 30 treatments and 10 additional treatments after any subsequent dilation(s). She underwent 30 treatments (2.4 atmosphere absolute, 115 minutes [U.S. Navy Treatment Table 9]) and had a subsequent upper endoscopy that showed healing of the esophageal ulcer and a benign appearing stenosis measuring 10 cm in length with a 10-mm inner diameter. The stricture was effectively dilated to 12 mm. Based on the favorable response, she underwent serial endoscopic dilations at 2-week intervals for a total of 5 endoscopic procedures and 2 additional postprocedural hyperbaric sessions of 10 treatments. Figure 1 summarizes her treatment plan. Her final upper endoscopy showed an esophageal diameter of 12 mm that was effectively dilated to 15 mm. Figure 2 depicts changes to her esophageal mucosal lining with successive hyperbaric oxygen and serial dilation.



**FIGURE 1.** Relationship of hyperbaric oxygen therapy and serial esophageal dilation procedures. Esophageal dilations performed at approximately 2-week intervals with hyperbaric oxygen treatments between dilations. Predilation diameter changes were less pronounced, and patient almost lost increase in stenotic diameter between 30th and 40th hyperbaric treatments. Note sustained predilation and postdilation esophageal diameter at the area of stenosis as the patient approaches 14 mm and 50 treatments.

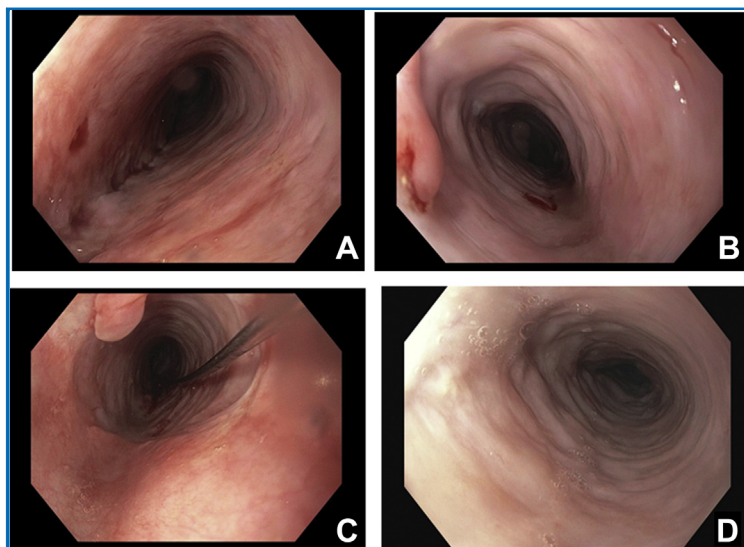
## DISCUSSION

The patient we have presented had a radiation-induced stricture that was effectively treated with serial esophageal dilations and adjuvant hyperbaric therapy. Esophageal stricture as the patient developed is evident with scar formation from fibrosis. Acute radiation-induced esophagitis is self-limited and generally does

not last more than 4 weeks after cessation of therapy. Radiation-induced stricture develops 3 to 8 months (median: 6 months) after completion of radiation therapy.<sup>14</sup> This patient had stricture 5 months after the completion of her radiation therapy, suggestive of late disease.<sup>15</sup> Radiation-induced strictures can develop in patients receiving limited treatment doses, particularly in the setting of concurrent chemotherapy.<sup>7</sup> Indeed, the literature is scarce on the adverse gastrointestinal effect of concurrent or sequential treatment with novel agents, such as nivolumab and cabozantinib, among patients receiving radiation therapy. A working knowledge of the pathophysiology of radiation-induced, immune-induced, and chemotherapy-related esophageal injury is crucial, as combination regimens are the mainstay of treatment for certain types of metastatic cancer.

Radiation-induced esophagitis is a dose-limiting complication of thoracic external beam radiation. It rarely occurs in patients exposed to 30 Gy or less of radiation. It has been estimated that less than 2% of patients treated with 50 Gy or less develop radiation-induced esophageal stricture, compared with 15% among patients treated with 60 Gy.<sup>16</sup> Our patient received 30 Gy: a routine palliative thoracic radiation dose below Radiation Therapy Oncology Group (RTOG)-recommended mean dose of 34 Gy. Despite this, she progressed from an acute esophagitis RTOG grade I to a grade III in 2 weeks. Predictors of radiation-induced esophagitis are not fully understood, and some patients with relatively small radiation doses have been reported to develop grade I to III esophagitis.<sup>17</sup> Intrinsic and extrinsic factors play different roles in severe radiation-induced esophagitis leading to fibrosis and formation of esophageal stricture. Genetic predisposition resulting from single-nucleotide polymorphisms of transforming growth factor beta 1 (TGF  $\beta$ -1) may present an intrinsic factor contributing to the development of severe radiation esophagitis.<sup>18</sup>

Ionizing radiation causes DNA damage that, in turn, activates proinflammatory cytokines and stress-induced signaling pathways, resulting in endarteritis, breakdown of collagen, and cellular death.<sup>19,20</sup> Pathologic markers include increased mucosal inflammation, epithelial thinning, and denudation.<sup>21</sup>



**FIGURE 2.** Biweekly endoscopic evaluation of lower esophagus. Mucosal appearance during serial EGD done every 2 weeks with interval hyperbaric oxygen treatments. Gradual reduction in erythematous areas and scattered ulcers as seen on the patient's first (A), second (B) and fourth (C) EGD. No appreciable ulcers or mucosal erythema noted on fifth EGD after 50 hyperbaric oxygen treatment and biweekly serial dilations (D). Note, third EGD was few days after the second EGD (not shown here). EGD = esophagogastroduodenoscopy.

These pathologic markers observed in radiation-induced esophagitis are similar to changes noted in caustic esophageal injury, suggesting a common underlying mechanism in the acute phase.<sup>7</sup> One animal study reported reduction in ulcer depths, vascular thrombosis, mortality, and collagen score among rats that had caustic distal esophageal injury among HBO-treated groups compared with the group that did not receive non-HBO.<sup>22</sup> It is biologically plausible to expect similar hyperbaric oxygen treatment benefit(s) to esophageal injury resulting from radiation therapy. Long-term sustained hypoxic state creates a tenuous microenvironment in which metabolic demands exceed supply and accelerate the formation of ulcers from a denuded epithelial lining. Wound healing in previously irradiated mucosa is therefore defective, and subsequent tissue disruption from procedures, such as dilation, is fraught with complications and recurrence and may benefit from adjuvant HBO to support the healing process.<sup>9</sup>

Cabozantinib is a multityrosine kinase inhibitor that acts against several receptors such

as VEGF-2, RET, c-MET, FLT3, and AXL. It inhibits VEGFR-2, HGF-c-MET, and RET angiogenesis pathways. One preclinical study reports inhibition of ongoing angiogenesis with sparing of established vessels.<sup>23</sup> It is not well known how inhibition of angiogenesis from cabozantinib differs from that of radiation. Another animal study that focused on tumor antiangiogenesis reported synergistic effect of concurrent radiation and chemotherapy.<sup>24</sup> Several clinical studies have reported that combining radiation and chemotherapy accelerates radiation-induced esophagitis and development of stricture.<sup>7,25,26</sup>

There is less evidence regarding adverse effects when extracranial palliative radiation is combined with immune checkpoint inhibitors such as anti-PD 1. Anti-PD 1 uncouples the brake-immune signal (PD 1/PD-L1), thereby increasing the baseline T-cell-specific immune response that activates the immune system against cancer cells. This T-cell-mediated action alters the immunologic homeostasis and exhibits autoimmune-like and inflammatory effects on normal tissues, involving B cells, granulocytes, and cytokines. As previously mentioned, concurrent radiation and anti-PD 1 have proinflammatory components, creating a “super-inflammatory” hypoxic field that may accelerate the development of esophagitis and formation of esophageal stricture, among other injuries.

In our patient, the rapid development of severe esophagitis and stricture after palliative thoracic radiation may be due to a process specific to cabozantinib or nivolumab, synergistic effects of concurrent administration of cabozantinib and nivolumab, or an underlying genetic predisposition that accelerated formation of stricture.

## OUTCOME

After completing serial dilations to an esophageal luminal diameter of 15 mm and 50 HBO treatments, the patient was ultimately able to tolerate a regular diet with no evidence of dysphagia or odynophagia. The PEG was removed 1 month after her third esophageal dilation. She has remained symptom free and without recurrence for 9 months.

## CONCLUSIONS

The successful relief of this patient's symptoms and restoration of regular dietary intake

supports the management of radiation-induced esophageal strictures with serial esophageal dilation and adjuvant HBO therapy. Concurrent use of novel chemotherapy agents (nivolumab and/or cabozantinib) may predispose patients to radiation injury regardless of dosage, and sequential therapy as an alternative should be considered. Preclinical studies are required to clarify the pathophysiologic mechanisms whereby the combined use of anti-PD 1 medications and radiation therapy may result in synergistic adverse events. Well-designed randomized trials and/or cohort studies are also needed to elucidate further the role of cabozantinib in accelerating radiation-induced injuries.

## ACKNOWLEDGMENTS

Dr Ajayi analyzed and interpreted the patient's hyperbaric oxygen (HBO)-related history, examination, and treatments. Dr Leggett analyzed and interpreted the patient's esophagogastroduodenoscopy and other gastroenterology-related treatments. Dr Myburgh analyzed and interpreted the patient's esophagogastroduodenoscopy and other gastroenterology-related treatments. Dr Hendriksen analyzed and interpreted the patient's HBO-related history, examination, and treatments. Dr Westgard analyzed and interpreted the patient's HBO-related history, examination, and treatments. Dr Logue analyzed and interpreted the patient's HBO-related history, examination, and treatments. Dr Walter analyzed and interpreted the patient's HBO-related history, examination, and treatments. Dr Masters analyzed and interpreted the patient's HBO-related history, examination, and treatments. All authors were major contributors to the writing of this article, and Dr Walter was a major contributor to the editing of the manuscript. All authors read and approved the final manuscript.

**Potential Competing Interests:** The authors report no competing interests

**Publication dates:** Received for publication February 27, 2019; revisions received March 28, 2019; accepted for publication April 1, 2019.

**Correspondence:** Address to Olayinka D. Ajayi, MD, Emergency Medicine Department, Hennepin Healthcare (Hennepin County Medical Center), 701 Park Avenue, PI.661, Minneapolis, MN 55415 ([olayinka.ajayi@hcmcd.org](mailto:olayinka.ajayi@hcmcd.org)).

## REFERENCES

1. Pal SK, Nelson RA, Vogelzang N. Disease-specific survival in de novo metastatic renal cell carcinoma in the cytokine and targeted therapy era. *PLoS One*. 2013;8(5):e63341.
2. Shek D, Tomlinson B, Brown M, et al. Epidemiologic trends in renal cell carcinoma in the cytokine and post-cytokine eras: a registry analysis of 28,252 patients. *Clin Genitourin Cancer*. 2012;10(2):93-98.
3. Vaishampayan U, Vankayala H, Vigneau FD, et al. The effect of targeted therapy on overall survival in advanced renal cancer: a study of the national surveillance epidemiology and end results registry database. *Clin Genitourin Cancer*. 2014;12(2):124-129.
4. Dragovic J, Doyle TJ, Tilchen EJ, et al. Accelerated fractionation radiotherapy and concomitant chemotherapy in patients with stage IV inoperable head and neck cancer. *Cancer*. 1995;76(9):1655-1661.
5. Nguyen NP, Sallah S. Combined chemotherapy and radiation in the treatment of locally advanced head and neck cancers. *In Vivo*. 2000;14(1):35-40.
6. Zhang MA, Trillis CM. Late development of esophageal stricture following radiation and chemotherapy for small cell carcinoma of the lung: a case report. *Cases J*. 2008;1(1):169.
7. Murro D, Jakate S. Radiation esophagitis. *Arch Pathol Lab Med*. 2015;139(6):827-830.
8. Tuna Y, Koçak E, Dinçer D, Köklü S. Factors affecting the success of endoscopic bougie dilatation of radiation-induced esophageal stricture. *Dig Dis Sci*. 2012;57(2):424-428.
9. Agarwalla A, Small AJ, Mendelson AH, Scott FI, Kochman ML. Risk of recurrent or refractory strictures and outcome of endoscopic dilation for radiation-induced esophageal strictures. *Surg Endosc*. 2015;29(7):1903-1912.
10. Marx RE. Osteoradionecrosis: a new concept of its pathophysiology. *J Oral Maxillofac Surg*. 1983;41(5):283-288.
11. Marx RE, Ehler WJ, Tayapongasak P, Pierce LW. Relationship of oxygen dose to angiogenesis induction in irradiated tissue. *Am J Surg*. 1990;160(5):519-524.
12. Thom SR. Oxidative stress is fundamental to hyperbaric oxygen therapy. *J Appl Physiol (1985)*. 2009;106(3):988-995.
13. Bennett MH, Feldmeier J, Hampson N, Smeee R, Milross C. Hyperbaric oxygen therapy for late radiation tissue injury. *Cochrane Database Syst Rev*. 2005;(3):CD005005.
14. O'Rourke IC, Tiver K, Bull C, GebSKI V, Langlands AO. Swallowing performance after radiation therapy for carcinoma of the esophagus. *Cancer*. 1988;61(10):2022-2026.
15. Baker S, Fairchild A. Radiation-induced esophagitis in lung cancer. *Lung Cancer (Auckl)*. 2016;13(7):119-127. <https://doi.org/10.2147/LCTT.S96443>.
16. Coia LR, Myerson RJ, Tepper JE. Late effects of radiation therapy on the gastrointestinal tract. *Int J Radiat Oncol Biol Phys*. 1995;31(5):1213-1236.
17. Metcalfe SK, Milano MT, Bylund K, et al. Split-course palliative radiotherapy for advanced non-small cell lung cancer. *J Thorac Oncol*. 2010;5(2):185-190.
18. Guerra JL, Gomez D, Wei Q, et al. Association between single nucleotide polymorphisms of the transforming growth factor  $\beta 1$  gene and the risk of severe radiation esophagitis in patients with lung cancer. *Radiother Oncol*. 2012;105(3):299-304.
19. Haimovitz-Friedman A. Radiation-induced signal transduction and stress response. *Radiat Res*. 1998;150(5 suppl):S102-S108.
20. Yu H. Typical cell signaling response to ionizing radiation: DNA damage and extranuclear damage. *Chin J Cancer Res*. 2012;24(2):83-89. <https://doi.org/10.1007/s11670-012-0083-1>.
21. Fajardo LF. The pathology of ionizing radiation as defined by morphologic patterns. *Acta Oncol*. 2005;44(1):13-22. <https://doi.org/10.1080/02841860510007440>.
22. Kiyan G, Aktas S, Ozel K, Isbilen E, Koriloglu E, Dagli TE. Effects of hyperbaric oxygen therapy on caustic esophageal injury in rats. *J Pediatr Surg*. 2004;39(8):1188-1193. <https://doi.org/10.1016/j.jpedsurg.2004.04.012>.
23. Benjamin LE, Golijanin D, Itin A, Podes D, Keshet E. Selective ablation of immature blood vessels in established human tumors follows vascular endothelial growth factor withdrawal. *J Clin Invest*. 1999;103(2):159-165.
24. Koo HJ, Lee M, Kim J, et al. Synergistic effect of anti-angiogenic and radiation therapy: quantitative evaluation with dynamic contrast enhanced MR imaging. *PLoS ONE*. 2016;11(2). [doi.org/10.1371/journal.pone.0148784](https://doi.org/10.1371/journal.pone.0148784).
25. Kasibhatla M, Clough RW, Montana GS, et al. Predictors of severe gastrointestinal toxicity after external beam radiotherapy and interstitial brachytherapy for advanced or recurrent gynecologic malignancies. *Int J Radiat Oncol Biol Phys*. 2006;65(2):398-403.
26. Baglan KL, Frazier RC, Yan D, Huang RR, Martinez AA, Robertson JM. The dose-volume relationship of acute small bowel toxicity from concurrent 5-FU-based chemotherapy and radiation therapy for rectal cancer. *Int J Radiat Oncol Biol Phys*. 2002;52(1):176-183.